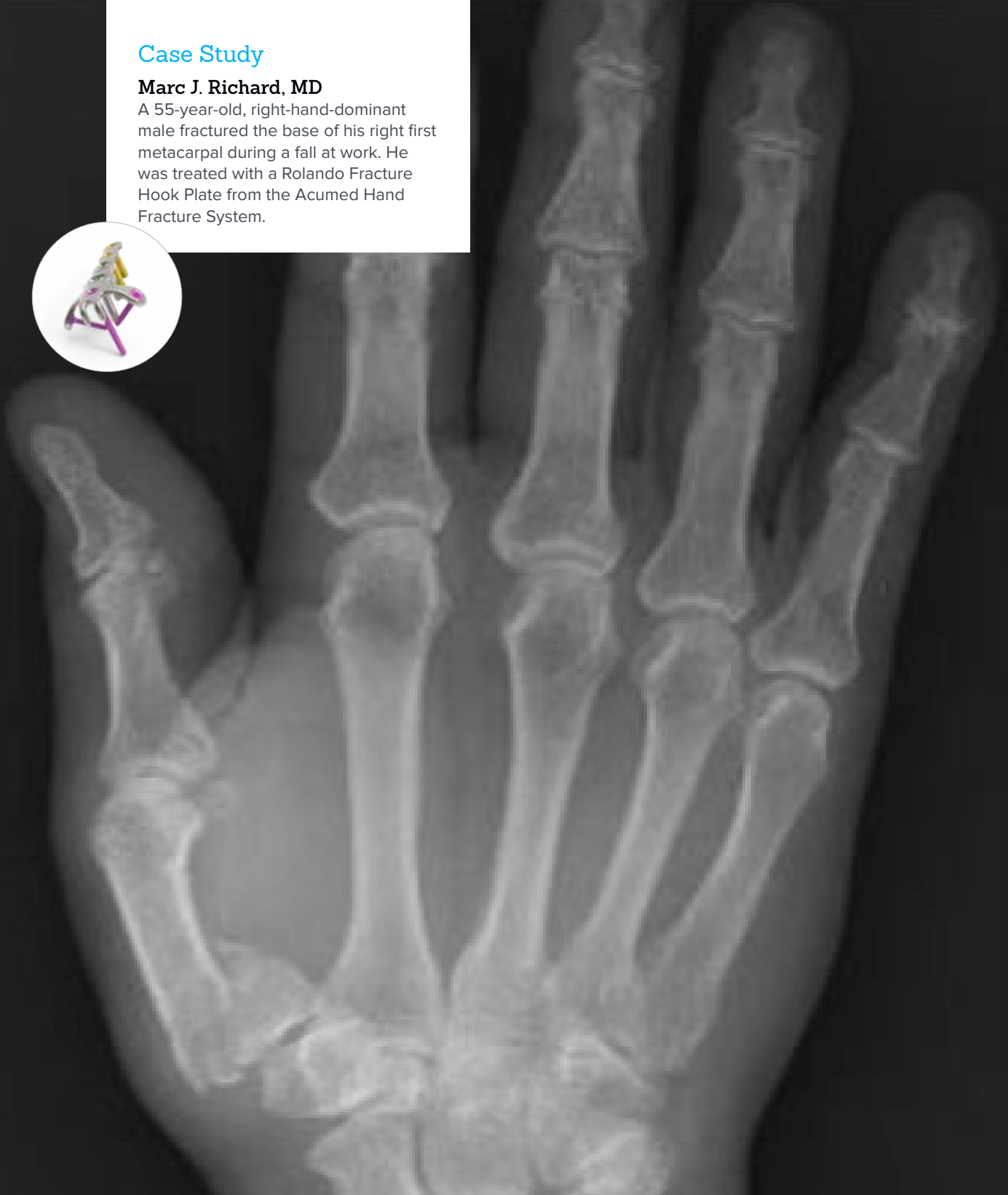


ORIF of First Metacarpal Base Fracture

Case Study

Marc J. Richard, MD

A 55-year-old, right-hand-dominant male fractured the base of his right first metacarpal during a fall at work. He was treated with a Rolando Fracture Hook Plate from the Acumed Hand Fracture System.

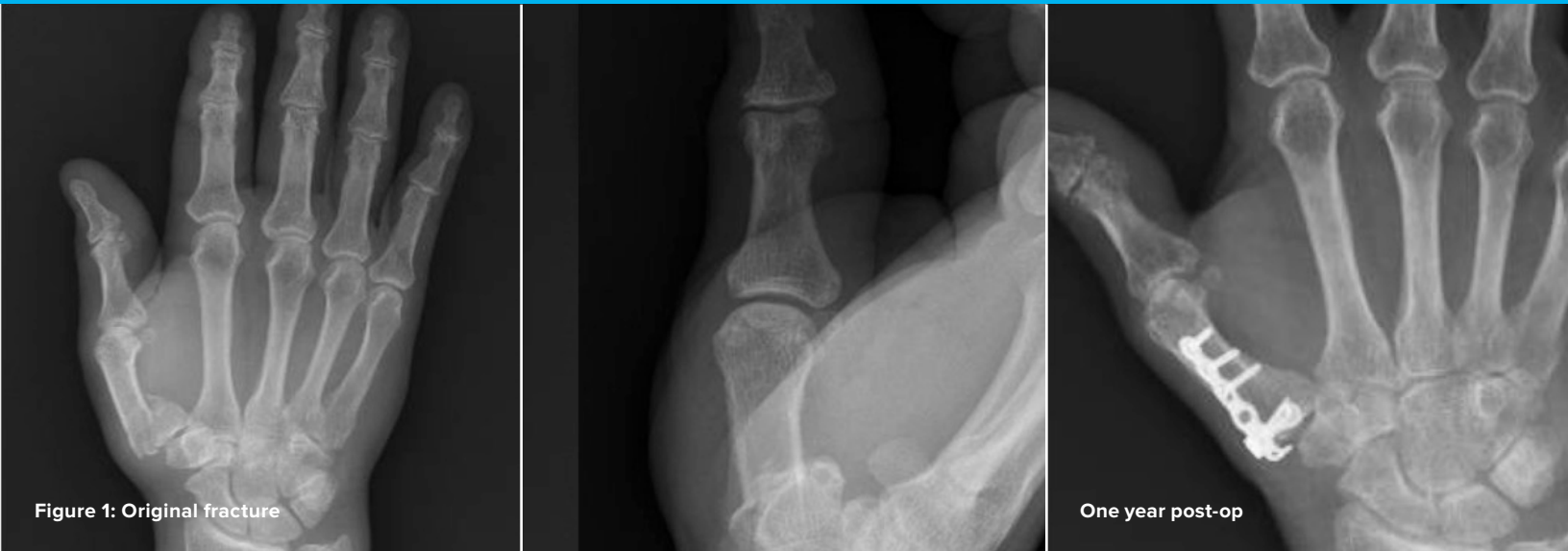

Acumed® is a global leader of innovative orthopaedic and medical solutions.



We are dedicated to developing products, service methods, and approaches that improve patient care.

Case Study | Marc J. Richard, MD



Open Reduction Internal Fixation (ORIF) of First Metacarpal Base Fracture

Patient History

A 55-year-old, right-hand-dominant male sustained a right first metacarpal base fracture during a fall at work. He presented to the emergency department where radiographs demonstrated a complete articular fracture of the base of the thumb (Figure 1). He was initially placed into a thumb spica splint and referred for definitive management.

Treatment

The patient was taken to the operating room and was placed supine on the operating table with a hand table attachment. The right upper extremity was prepped and draped in the usual sterile fashion. Traction views of the thumb were obtained prior to making surgical incision and confirmed a complete articular fracture pattern. The surgical incision was then made over the glabrous/non-glabrous border of the thumb centered over the metacarpal base. Care was taken to identify and protect the terminal branches of the superficial radial and lateral antebrachial cutaneous nerves. The abductor pollicis longus (APL) and extensor pollicis brevis (EPB) tendons were identified. The dorsal branch of the radial artery is at the proximal aspect of the incision and reliably marks the scapho-trapezio-trapezoidal (STT) joint. This was identified and protected throughout the case. The periosteum of the metacarpal was divided longitudinally between the EPB and the insertion of APL. Full thickness flaps were elevated and preserved for later coverage of the plate during closure.

The fracture fragments were identified and debrided of fracture hematoma. Provisional fracture reduction was obtained with a pointed reduction clamp across the articular fragments and a 0.045" K-wire placed longitudinally through the metacarpal into the trapezium. After reduction was obtained, the 1.3 mm Rolando Fracture Hook Plate from the Acumed Hand Fracture System was placed on the dorsal aspect of the first metacarpal. The hook on the proximal aspect of the plate is positioned on the insertion of the APL onto the metacarpal base. A pointed reduction clamp and 0.040" Plate Tack was used to hold the plate aligned to the metacarpal (Figure 2). C-arm fluoroscopy was used to confirm appropriate reduction and plate placement.

A 2.3 mm hexalobe lag screw was placed through the oblong hole on the shaft. Attention was then turned to the proximal screw holes which were sequentially filled with 1.5 mm Hexalobe MultiScrews. The remainder of the shaft screws were placed and fluoroscopy confirmed the final reduction on orthogonal views (Figure 3). The K-wire was left in place for supplemental fixation due to significant comminution of one of the articular fragments. The periosteum was closed over the plate, preserving the gliding surface for the EPB tendon. The skin was closed using interrupted nylon sutures and the patient was placed into a thumb spica splint.

Postoperative Care

With the rigid fixation obtained in the operating room, the patient was seen in clinic on post-op day 3 for fabrication of a removable splint and initiation of range of motion exercises for the interphalangeal and metacarpophalangeal joints. The hand therapist made a custom hand-based thumb spica orthosis and instructed the patient on the range of motion exercises.

The patient worked on progressive range of motion and edema control. Although early healing is not a typical result, at 4 weeks post-op, radiographs demonstrated maintenance of reduction and early healing (Figure 4). The K-wire was removed in clinic and range of motion was advanced to include the carpometacarpal (CMC) joint. Serial clinical examination and radiographs documented progressive functional improvement and fracture union. (The prongs on the proximal end of the 1.3 mm Rolando Fracture Hook Plate are not intended to compress the APL tendon down to the bone and a gap may be visible between the plate prongs and the bone on X-ray.)

At 1 year post-op (Figure 5), the patient showed healing clinically and radiographically. The patient achieved composite thumb opposition to the base of the small finger. At the time of follow-up, his lateral pinch was symmetric to his contralateral side.

Discussion

The eponym "Rolando fracture" is commonly used to describe complete articular fractures of the base of the thumb metacarpal. These fractures require anatomic restoration of the articular surface with subsequent reattachment to the shaft fragment. The Acumed Rolando Fracture Hook Plate is designed to allow for intra-operative plate alignment that places the screw holes over the common fracture fragments and aligns with the unique anatomy of the proximal metacarpal base. Though early range of motion is not an expected result for all patients, in this case the resultant construct and fracture fixation was rigid enough to initiate early range of motion.

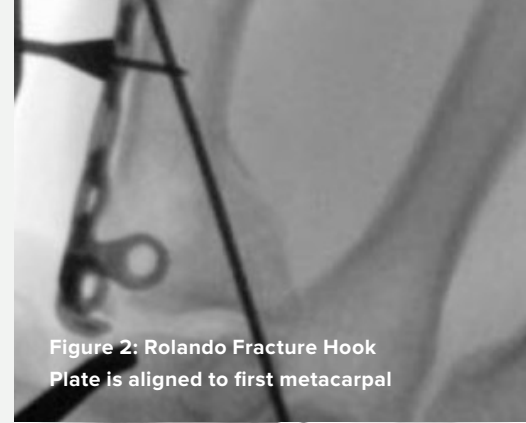


Figure 2: Rolando Fracture Hook Plate is aligned to first metacarpal

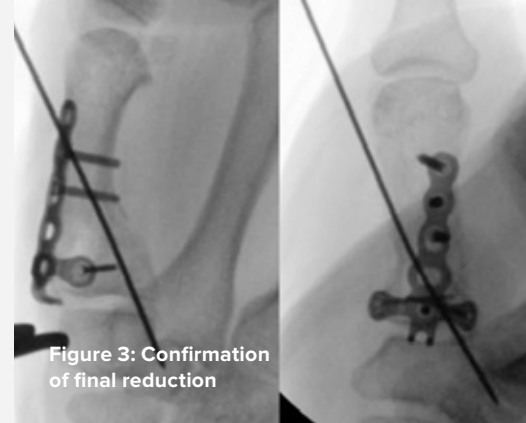


Figure 3: Confirmation of final reduction

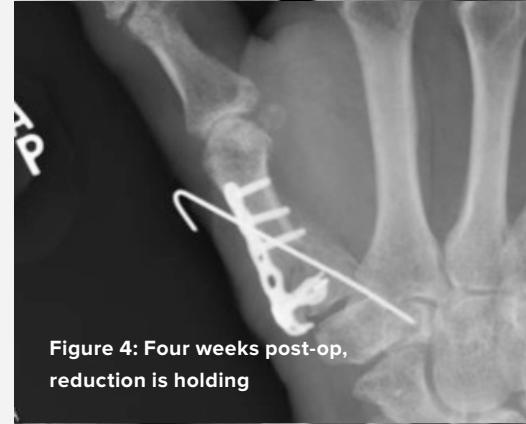

Figure 4: Four weeks post-op, reduction is holding

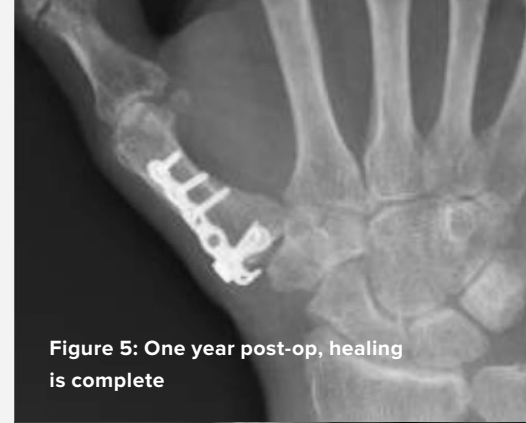
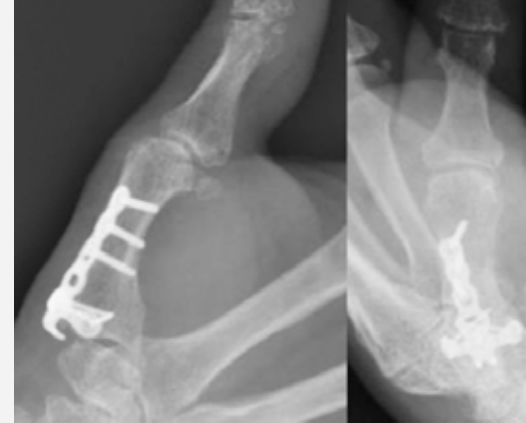
Figure 5: One year post-op, healing is complete





HNW70-11-A

Effective: 2017/08

© 2017 Acumed® LLC

Acumed® Headquarters
5885 NW Cornelius Pass Road
Hillsboro, OR 97124
Office: 888.627.9957
Fax: 503.520.9618
www.acumed.net

These materials contain information about products that may or may not be available in any particular country or may be available under different trademarks in different countries. The products may be approved or cleared by governmental regulatory organizations for sale or use with different indications or restrictions in different countries. Products may not be approved for use in all countries. Nothing contained on these materials should be construed as a promotion or solicitation for any product or for the use of any product in a particular way which is not authorized under the laws and regulations of the country where the reader is located. Specific questions physicians may have about the availability and use of the products described on these materials should be directed to their particular authorized Acumed distributor. Specific questions patients may have about the use of the products described in these materials or the appropriateness for their own conditions should be directed to their own physician.

