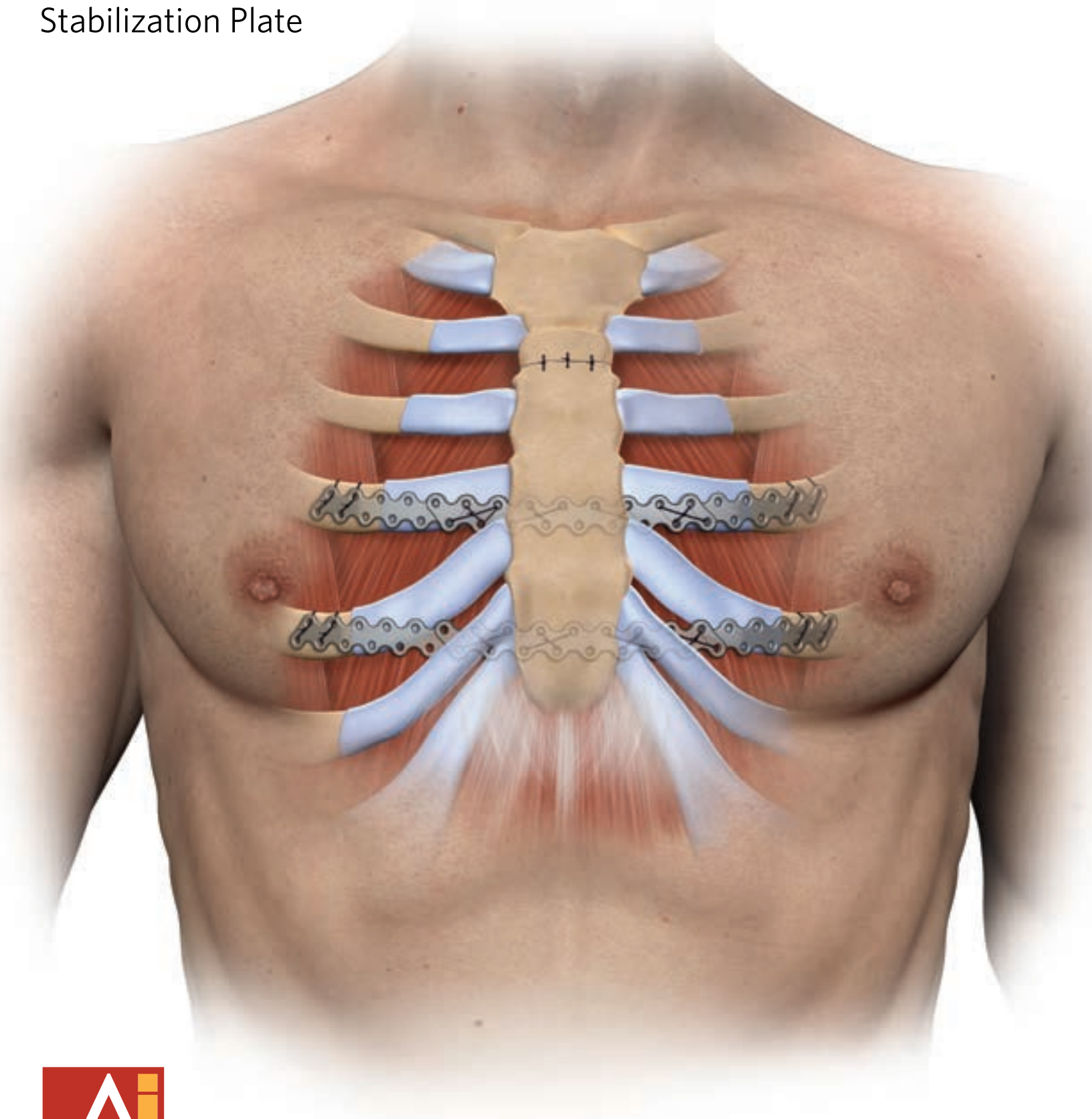


BioBridge[®]

Resorbable Chest Wall
Stabilization Plate

Open Pectus Repair
Technique



Innovative Solutions for Challenging Thoracic Procedures

PECTUS REPAIR

Statement from ACUTE Innovations®: The goal of this monograph is to describe a novel technique to help stabilize the sternum posteriorly after a modified Ravitch repair for pectus defects.

BioBridge is composed of absorbable material that is used to enhance the stability of the sternum at the time of an open repair. This technique provides stability through the timed support of the sternal repair with the goal of obtaining long-term stability through the natural healing of tissue and cartilage, thus preventing recurrence of the pectus deformity.

This handout is intended for support and educational purposes and is not to be used in any other capacity. All questions regarding surgical implantation of this product should be directed to a licensed medical professional familiar with ACUTE Innovations product. In addition, consult the product 'Instructions for Use' for more detailed product information.



Daniel Miller, MD

Chief, General Thoracic Surgery
Wellstar Health System

OVERVIEW

For years, the open Ravitch repair has been the standard surgical procedure for repair of pectus deformities. Recently, a resorbable BioBridge plate was developed that can be used to help stabilize the sternum at the time of the open pectus repair. The plate maintains full strength for 180 days and is absorbed in 2-3 years, thus avoiding a second procedure.

This modified Ravitch repair involves excising the deformed cartilage, usually 3 through 7 bilaterally while preserving the perichondrium. An anterior wedge osteotomy of the sternum is performed just below the Angle of Louis, which corrects the sternum deformity. The BioBridge is used to reinforce the sternum posteriorly and is anchored, on either side, to the anterior aspect of the ribs, usually the 4th and/or 5th.

The following technique describes a modified Ravitch procedure using the BioBridge Resorbable Chest Wall Stabilization Plate.

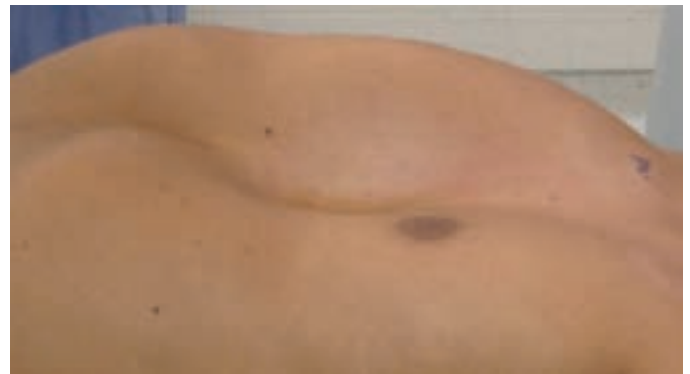Preoperative Patient Evaluation

Evaluation of a patient with a pectus deformity includes a CT scan of the chest with calculation of a Pectus Index (PI) and documentation of sternal symmetry, a 2-D echocardiogram to assess right ventricular function, and pulmonary function tests to rule out primary lung disease. The patient's symptoms in regards to pain, exercise capability and breathing difficulty should be detailed.

Notes:

- Calculation of the pectus index (by a chest CT scan) and sternal symmetry is needed to determine if an open or closed (Nuss) procedure is most appropriate.
- BioBridge is to be used in addition to the Ravitch procedure and is not intended to replace a metal strut alone.
- Use of the BioBridge plate in pediatric cases has not been cleared by the FDA. The BioBridge indications for use are located on the backside of this monograph.

Figure 1: Preoperative pectus defect



Recommended Preoperative Checklist

- **Suture:** A non-absorbable suture, USP size 2 with a CTX needle
- **Redo sternal saw:** For anterior wedge osteotomy of the sternum
- **BioBridge plates:** The number of plates needed depends on the width of the patient's chest cavity and on the preoperative severity of the defect. At least 6 plates should be available
- **Periosteal elevators:** For removing costal cartilage from within the perichondrium

Training

In preparation for the procedure, it is recommended that the OR personnel be trained on the technique for stacking and suturing the BioBridge plates together (Figure 4) and on the equipment necessary for the procedure.

PECTUS DEFORMITY REPAIR TECHNIQUE

Incision

For males, create a vertical midline incision from the fourth rib to the xiphoid. For females, an inframammary incision is used. Using electrocautery, the pectorals major muscles are dissected free from the chest wall and sternum so that abnormal cartilage may be identified for removal.

Remove Costal Cartilage

Once the sternum and costal cartilage are visualized, remove the cartilage where the defect begins. Remove the cartilage in a subchondral plane to preserve the perichondrium from the sternum to the ribs. Separate the perichondrium from the sternal edge and detach the xiphoid from the sternum keeping the rectus muscles attached to the xiphoid (Figure 2).

Sternal Elevation

Create an anterior wedge sternal osteotomy below the Angle of Louis to overcorrect the sternum anteriorly. U-stitches are used across the sternum osteotomy to stabilize the position.

Figure 2: Cartilage removed, perichondrium preserved, and wedge osteotomy sutured

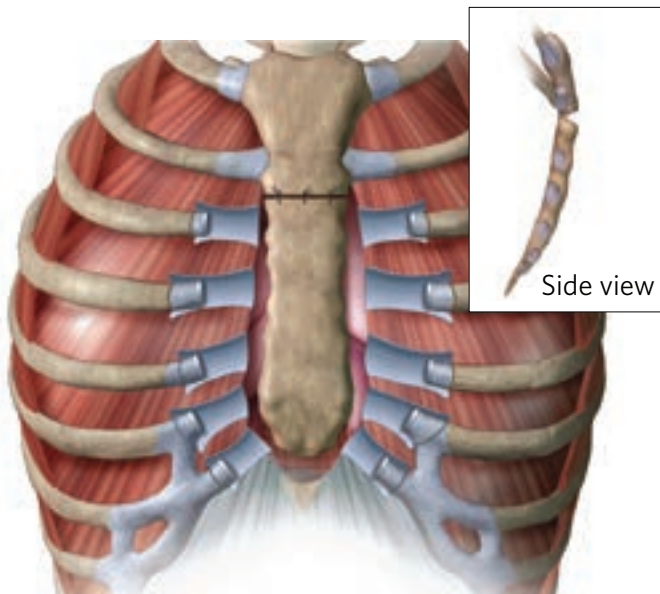
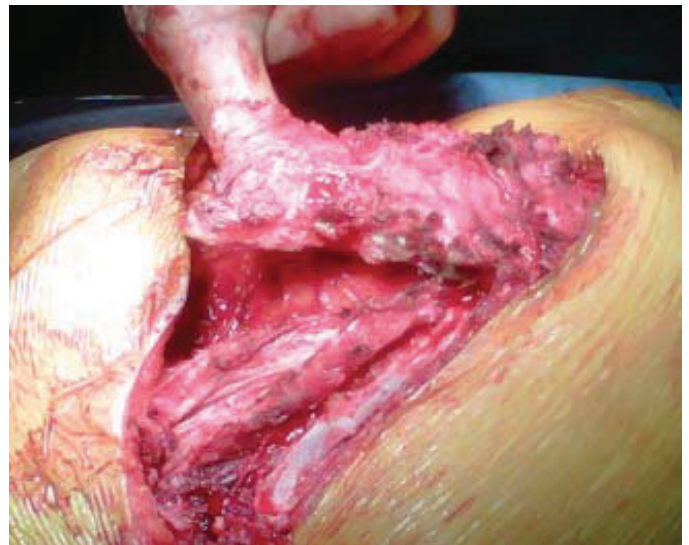

Figure 3: Sternum after freeing the cartilage




Preparation of BioBridge® Plates

BioBridge plates are sutured together to create a stabilizer of appropriate length. When planning the length of the stabilizer measure the distance between the planned anchor ribs bilaterally and account for at least 4 holes (1cm) overlap with the rib at each anchor point. Use non-absorbable sutures to stack two or three BioBridge plates together as a “doublet” or “triplet” stabilizer.

When stacking, overlap at least 4 holes to ensure each overlapping hole is sutured together, then add suture around the scallops in the plate to ensure a rigid construct (Figure 4).

! **IMPORTANT:** The stacked stabilizer must be rigid. If the final construct is loose, remove any loose sutures and re-tie them. Add BioBridge plates if additional stiffness is necessary.

Figure 4: Suture through the holes and around the scallops of the plates in order to achieve a tight stabilizer construct



INSTALLATION

Place the BioBridge stabilizer posterior to the sternum and anchor each end anteriorly on the ribs. Secure the BioBridge stabilizer by passing the CTX suture needle through the superior and inferior holes of the plate. Then wrap the suture around the rib posteriorly and anteriorly and through the intercostal muscles using a figure of eight or simple interrupted suture. Additional suture may be wrapped around the BioBridge plate and bone to add stability. Test the rigidity of the supported sternum. An additional BioBridge stabilizer may need to be added to increase rigidity (Figure 5).

Once the anatomical correction is made, re-attach the xiphoid and the perichondrial beds to the newly positioned sternum (Figures 5 and 6).

Figure 5: BioBridge stabilizers installed, inset showing suture at anchor points

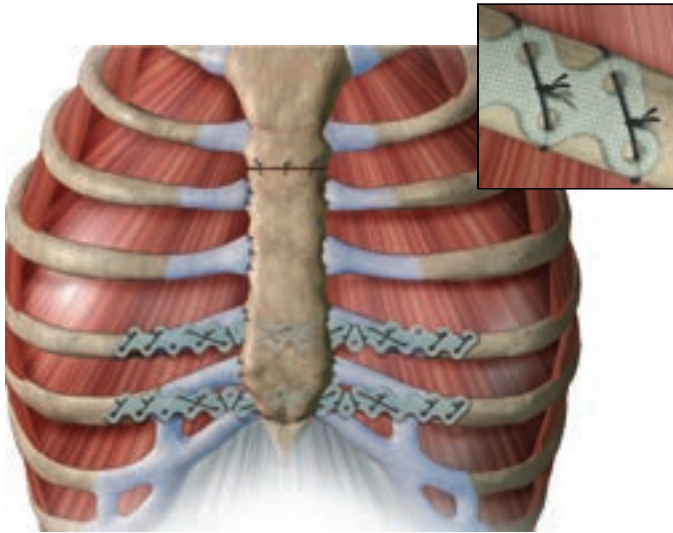
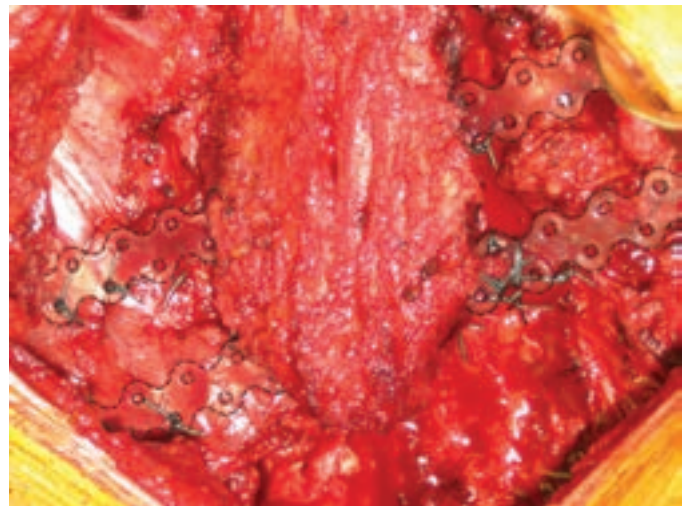


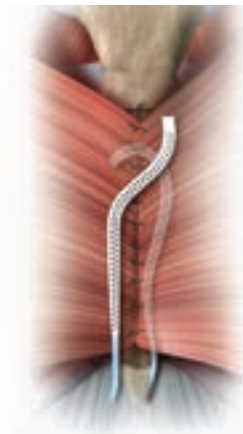Figure 6: Plates installed and perichondrium re-attached



Note:

- BioBridge stabilizers are highlighted in this image for visibility

Figure 7: Closure showing placement of drains



Closure

Reapproximate the pectoralis major muscle and subcutaneous tissues, followed by a subcuticular skin closure. Two 10mm Jackson-Pratt drains are routinely placed anterior and posterior to the pectoralis muscles. If the pleura is violated a 19 Fr Blake is placed in the pleural space (Figure 7).

Postoperative

An epidural is used for postoperative pain management. The patients are monitored on a regular telemetry floor. All drains are usually removed on postoperative days 3 or 4 in the majority of the patients. If the drainage is excessive, the patient is discharged and monitored until drainage is <50mL/day. All patients are fitted with a protective shield to protect the soft, anterior chest. The shield is typically worn for 6 to 8 weeks. Follow up appointments are conducted at 3-4 weeks, 3 months, and 6 months.

APPENDIX

For additional information on the BioBridge Resorbable Chest Wall Stabilization Plate, contact your local ACUTE Innovations sales representative or visit: www.acuteinnovations.com

BioBridge® Plate Indications

In the presence of appropriate additional immobilization or fixation, indicated for maintaining the alignment and fixation of bone fractures, osteotomies, arthrodeses or bone grafts, and maintenance of relative position of weak bony tissue (e.g. bone grafts, bone graft substitutes, or bone fragments from comminuted fractures), in trauma and reconstructive procedures.

Specific indications:

- Metacarpus, proximal and middle phalangeal bones
- Long bones, flat bones, short bones, irregular bones, appendicular skeleton, and thorax



- 1 Luu TD, Kogon BE, Force SD, Mansour KA, Miller DL. Surgery for recurrent pectus deformities. *Ann Thorac Surg.* 2009 Nov;88(5):1627-31.
- 2 Mansour KA, Thourani VH, Odessey EA, Durham MM, Miller JI Jr, Miller DL. Thirty-year experience with repair of pectus deformities in adults. *Ann Thorac Surg.* 2003 Aug;76(2):391-5; discussion 395.



Back to health. Back to work. Back to **life.**



8055 NE Jacobson Street
Suite 700
Hillsboro, OR 97124

1-866-623-4137

+1-503-686-7200

ACUTE Innovations® www.acuteinnovations.com

RRP7119_C | Effective: 6/2018

an  acumed® company