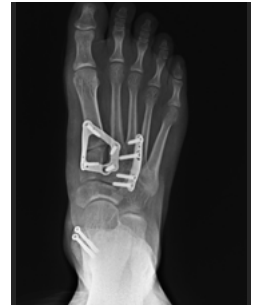

Case Study

Restoring Midfoot Stability and Function: Use of Lisfranc Stabilization Bridge Plate in Managing Midfoot Fractures and Ligamentous Instability of the First Through Third Tarsometatarsal (TMT) Joints



Christopher Diefenbach, MD

Northern Arizona Healthcare
Flagstaff, AZ

Dr. Diefenbach is the Orthopedic Service Line Medical Director at Northern Arizona Healthcare – Orthopedic and Spine Institute. He received his medical degree from NYU School of Medicine, and then completed his orthopedic surgery residency at UPMC Hamot. After completing his residency, he went on to complete his Foot and Ankle Fellowship at UC Davis. Dr. Diefenbach has experience treating orthopedic injuries for athletic teams. He has published numerous papers and focuses on forefoot, midfoot, hindfoot, and ankle care.

Patient History

A 21-year-old healthy active male sustained numerous midfoot avulsion fractures of the first through third tarsometatarsal (TMT) joints.

The patient was initially evaluated in the emergency department after landing awkwardly on the extremity at a trampoline park. He landed on the foot in a plantarflexed position, rolling the dorsal foot underneath himself. He underwent splinting at that time with advanced demonstrated avulsion fractures and instability of the first through third tarsometatarsal joints. The patient then maintained non-weight bearing, elevation, and icing in a splint until the soft tissues allowed for surgical intervention.

The patient was subsequently seen in the outpatient orthopedic clinic with transition into a cam walker boot while remaining non-weight bearing. This allowed evaluation of soft tissues which became amenable to surgical intervention three weeks following injury. The plan for open reduction and internal fixation with bridge plating was then discussed with the patient and his consent was obtained.

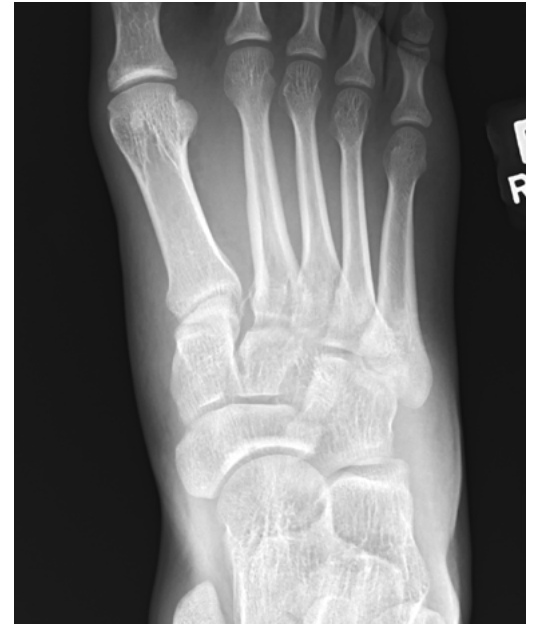Intraoperative Treatment

The patient was placed in a supine position with appropriate hip bump to hold the foot in a neutral position following peripheral nerve block administration by anesthesia. A two-incision direct dorsal approach was utilized overlying the first and third TMT joints. Careful dissection was performed with periosteal elevation on the dorsum of the midfoot. The neurovascular bundle was identified, mobilized and protected throughout the case.

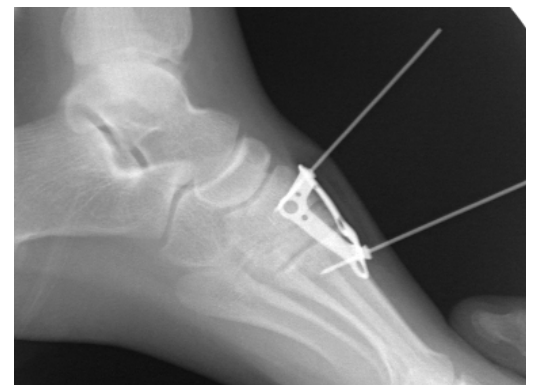
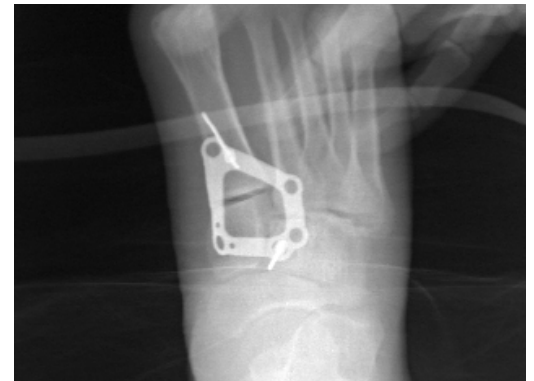
There was found to be diastasis and instability of the first, second, Lisfranc, and third TMT joints with associated avulsion fractures. The fourth and fifth TMT joints were successfully visualized through the lateral incision. These, as well as the intercuneiform joints, were found to be stable with manual stress prior to any fixation. The chondral surfaces were found to be in excellent condition.

The medial column was reduced first, and held in place with a pointed reduction clamp. Appropriate reduction of first TMT joint congruity and medial column line was confirmed fluoroscopically. A pointed reduction clamp was then utilized to reduce the second TMT as well as the Lisfranc joint. A/P and lateral views fluoroscopy confirmed alignment of the medial border of the second metatarsal base with the middle cuneiform and congruity of the second TMT joint. At this point an appropriate size Stabilization "Diamond" plate was selected from the ExtremiLock Lisfranc Module. Threaded olive wires were placed within the middle cuneiform and first metatarsal to maintain position, and confirmed with A/P and lateral fluoroscopy for appropriate size and position of the plate.

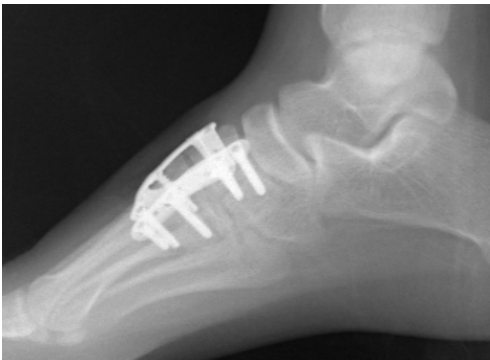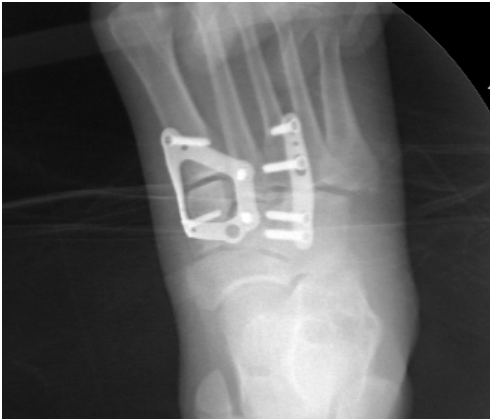
Preoperative



Intraoperative



Intraoperative



While maintaining position, cortical screws were then placed sequentially in the medial cuneiform, first metatarsal, middle cuneiform, and second metatarsal. The metatarsal screws were placed in a compressive manner. Fluoroscopic A/P and lateral views were obtained to confirm appropriate placement of hardware screw length and reduction.

Attention was then turned to the third TMT joint. Reduction was performed with a pointed reduction clamp and an appropriate straight plate was placed over the third TMT joint. Appropriate length cortical and locking screws were placed. The clamp was removed and satisfactory reduction and hardware placement were confirmed with A/P and lateral imaging. The fourth and fifth TMT joints were again found to be stable on visual inspection and imaging under dorsal and lateral stress.

Upon final fixation, the wounds were copiously irrigated and closed in a layered fashion.

Sterile dressings were applied with a well padded posterior splint and the patient was discharged home.

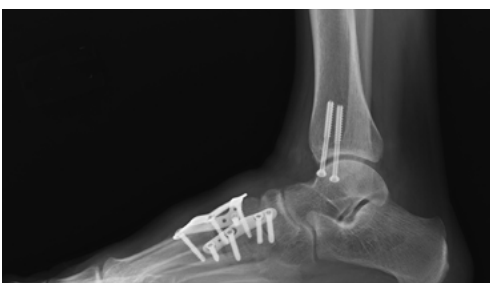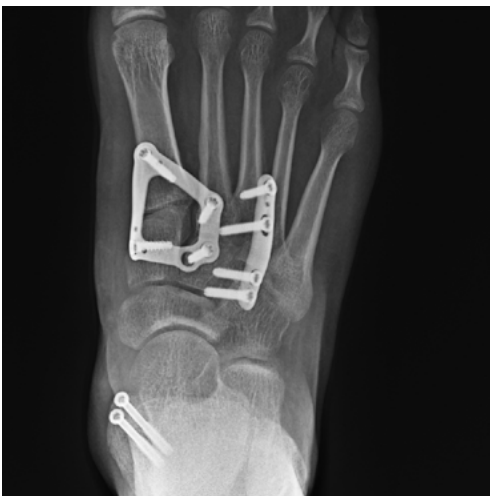Postoperative Treatment

The patient remained non-weight-bearing for two weeks. In the first two weeks the splint was maintained with elevation and soft tissue swelling control. The sutures were removed at two weeks, and he was transitioned to a cam walker boot with heel weight bearing, and allowed removal for hygiene, range of motion, and physical therapy. At six weeks, the patient was allowed to gradually increase to full weight bearing in the boot with arch support followed by self-weaning from boot to normal shoe with arch support along with compression stockings for edema control. Follow-up at three months revealed a return to walking in regular shoes and maintained alignment.

Discussion

The multitude of midfoot fracture and ligamentous injury variations calls for for a wide variety of fixation techniques and individualized treatment options to maximize results. The complement of Acumed midfoot plates and screws allowed me the flexibility to custom tailor this patient's fixation. The available Lisfranc Stabilization "Diamond" Plate offers robust tarsometatarsal joint fixation while sparing the soft tissue dissection required to span the length of the metatarsals. Additionally, the pre-contouring of the plate was found to fit the patient anatomically.

Postoperative





FNA70-18-A

Effective: 2024/05

© 2024 Acumed® LLC

www.acumed.net

Acumed USA Campus
5885 NE Cornelius Pass Road
Hillsboro, OR 97124
+1.888.627.9957

OsteoMed USA Campus
3885 Arapaho Road
Addison, TX 75001
+1.800.456.7779

Acumed Iberica Campus
C. Proción, 1
Edificio Oficor
28023 Madrid, Spain
+34.913.51.63.57

These materials contain information about products that may or may not be available in any particular country or may be available under different trademarks in different countries. The products may be approved or cleared by governmental regulatory organizations for sale or use with different indications or restrictions in different countries. Products may not be approved for use in all countries. Nothing contained on these materials should be construed as a promotion or solicitation for any product or for the use of any product in a particular way which is not authorized under the laws and regulations of the country where the reader is located. Specific questions physicians may have about the availability and use of the products described on these materials should be directed to their particular authorized Acumed distributor. Specific questions patients may have about the use of the products described in these materials or the appropriateness for their own conditions should be directed to their own physician.

Acumed® is a registered trademark of Acumed LLC.